

See discussions, stats, and author profiles for this publication at: <https://www.researchgate.net/publication/282912692>

Prevention of increased abnormal fundus autofluorescence with blue light-filtering intraocular lenses

Article in *Journal of Cataract and Refractive Surgery* · October 2015

DOI: 10.1016/j.jcrs.2015.01.017

CITATION

1

READS

58

8 authors, including:



Yoshio Hirano

Nagoya City University

43 PUBLICATIONS 738 CITATIONS

SEE PROFILE



Tsutomu Yasukawa

Nagoya City University

79 PUBLICATIONS 1,113 CITATIONS

SEE PROFILE



Ute E K Wolf-Schnurrbusch

Inselspital, Universitätsspital Bern

37 PUBLICATIONS 1,158 CITATIONS

SEE PROFILE



Sebastian Wolf

Inselspital, Universitätsspital Bern

329 PUBLICATIONS 6,031 CITATIONS

SEE PROFILE



Prevention of increased abnormal fundus autofluorescence with blue light-filtering intraocular lenses

Hiroyuki Nagai, MD, Yoshio Hirano, MD, PhD, Tsutomu Yasukawa, MD, PhD, Hiroshi Morita, MD, Miho Nozaki, MD, PhD, Ute Wolf-Schnurrbusch, MD, PhD, Sebastian Wolf, MD, PhD, Yuichiro Ogura, MD, PhD

PURPOSE: To observe changes in fundus autofluorescence 2 years after implantation of blue light-filtering (yellow-tinted) and ultraviolet light-filtering (colorless) intraocular lenses (IOLs).

SETTING: Department of Ophthalmology and Visual Science, Nagoya City University Graduate School of Medical Sciences, Nagoya, Japan, and the Department of Ophthalmology, University of Bern, Bern, Switzerland.

DESIGN: Prospective comparative observational study.

METHODS: Patients were enrolled who had cataract surgery with implantation of a yellow-tinted or colorless IOL and for whom images were obtained on which the fundus autofluorescence was measurable using the Heidelberg Retina Angiogram 2 postoperatively. The fundus autofluorescence in the images was classified into 8 abnormal patterns based on the classification of the International Fundus Autofluorescence Classification Group. The presence of normal fundus autofluorescence, geographic atrophy, and wet age-related macular degeneration (AMD) also was recorded. The fundus findings at baseline and 2 years postoperatively were compared.

RESULTS: Fifty-two eyes with a yellow-tinted IOL and 79 eyes with a colorless IOL were included. Abnormal fundus autofluorescence did not develop or increase in the yellow-tinted IOL group; however, progressive abnormal fundus autofluorescence developed or increased in 12 eyes (15.2%) in the colorless IOL group ($P = .0016$). New drusen, geographic atrophy, and choroidal neovascularization were observed mainly in the colorless IOL group. The incidence of AMD was statistically significantly higher in the colorless IOL group ($P = .042$).

CONCLUSIONS: Two years after cataract surgery, significant differences were seen in the progression of abnormal fundus autofluorescence between the 2 groups. The incidence of AMD was lower in eyes with a yellow-tinted IOL.

Financial Disclosure: No author has a financial or proprietary interest in any material or method mentioned.

J Cataract Refract Surg 2015; 41:1855–1859 © 2015 ASCRS and ESCRS

Previous population-based studies^{1–3} have shown that cataract surgery might increase the risk for developing age-related macular degeneration (AMD). The factors of intraocular surgery that might increase the incidence are intraoperative light exposure, intraoperative changes in intraocular pressure, postoperative inflammation, and postoperative increases in intravitreal oxygen partial pressure. In addition, because cataract surgery specifically affects the incidence of AMD, a vitreous liquefaction-related increase in vitreomacular

traction and postoperatively enhanced blue-light hazard through an intraocular lens (IOL) are among the risk factors.

With aging, the rate of light transmission, especially blue light, of the human crystalline lens decreases; however, in eyes with a colorless nontinted (colorless) IOL, the transmission rate of blue light is well beyond physiologic levels. In contrast, yellow-tinted IOLs are comparable to the crystalline lens in young eyes in terms of light transmission. Implantation of a yellow-

tinted IOL potentially reduces the postoperative blue-light hazard as a risk factor for cataract surgery for AMD.

Fluorescence confocal laser ophthalmoscopy can measure fundus autofluorescence, and the measurements provide specific significant findings related to disrupted retinal pigment epithelium (RPE) in eyes with AMD or other diseases.⁴ Lois et al.⁵ reported that alterations in fundus autofluorescence were not necessarily associated with corresponding fundoscopic visible drusen or irregular pigmentation, which might be earlier signs of fundus changes. Thus, fundus autofluorescence imaging might detect earlier or more subtle fundus changes after cataract surgery.

The purpose of the present study was to observe changes in fundus autofluorescence and on fundus photographs for 2 years after implantation of a blue light-filtering (yellow-tinted) or ultraviolet (UV) light-filtering (colorless) IOL to evaluate the potential of yellow-tinted IOLs to prevent AMD.

PATIENTS AND METHODS

This prospective multicenter comparative observational study was performed at Nagoya City University, Japan, and the University of Bern, Switzerland, according to the guidelines of the Declaration of Helsinki. It was approved by the internal review boards of both universities, and all patients provided written informed consent.

Patients were enrolled who had uneventful cataract surgery with implantation of a yellow-tinted IOL (YA-60BBR, Hoya Corp.) or a colorless IOL (VA-60BBR, Hoya Corp.) performed by experienced surgeons at Nagoya City University (Y.H., T.Y., H.M., M.N.) and the University of Bern (U.W., S.W.) from April 2007 to July 2010 and whose images with fundus autofluorescence were obtainable using the

Heidelberg Retina Angiograph 2 (Heidelberg Engineering GmbH) immediately after surgery. When both eyes of a patient had cataract surgery, the first eye was included in the study. The exclusion criteria were the presence of AMD, diabetic retinopathy, glaucoma, or high myopia of -6.0 diopters or more.

Readers at the Bern Photographic Reading Center who were masked to the patient data selected 9 or more consecutive single images for automatic alignment to amplify the autofluorescence signal and then classified the averaged image for each of the 9 sectors as defined by the Early Treatment Diabetic Retinopathy Study.⁶ The fundus autofluorescence was classified into 8 abnormal patterns according to the International Fundus Autofluorescence Classification Group (ie, nearly normal, reticular, speckled, focal-increased, lace-like, linear, focal-plaque, and patchy) as well as normal fundus autofluorescence, newly formed drusen, geographic atrophy, wet AMD, and ungradable because of poor image quality.⁴ Fundus autofluorescence images and color fundus photographs were taken immediately postoperatively and 2 years postoperatively, from which the findings in each macular sector were compared.

The development, progression, or decrease in abnormal fundus autofluorescence; the presence or absence of drusen; and the development of wet AMD or geographic atrophy were assessed between the 2 study groups. A Fisher exact test (SAS software, SAS Institute, Inc.) was used for all analyses. A *P* value less than 0.05 was considered statistically significant.

RESULTS

Of the 174 eyes enrolled in the study, 43 (22 with yellow-tinted IOL; 21 with colorless IOL) were excluded because no fundus autofluorescence image was obtained at the 2-year evaluation because the patients did not complete the visit or because of posterior capsule opacification. The analysis was performed on data from 52 eyes with a yellow-tinted IOL and 79 eyes with a colorless IOL. The demographic and clinical profiles of the patients did not differ significantly between the 2 IOL groups (Table 1).

In the yellow-tinted IOL group, abnormal fundus autofluorescence did not develop or increase in size or density in any eye. Abnormal fundus autofluorescence developed or progressed in 12 eyes (15.2%) in the colorless IOL group (Figure 1); the difference between groups was statistically significant ($P = .0016$). In contrast, the abnormal fundus autofluorescence decreased in 3 eyes in the yellow-tinted IOL group and in 2 eyes in the colorless IOL group. Age-related macular degeneration (wet AMD or geographic atrophy) developed in 1 eye (1.9%) in the yellow-tinted IOL group and in 9 eyes (11.4%) in the colorless IOL group, and the incidence of AMD was statistically significantly higher in the colorless IOL group ($P = .042$). The type of AMD in the yellow-tinted IOL group was geographic atrophy, whereas geographic atrophy developed in 6 eyes and wet AMD in 3 eyes in the colorless IOL group. Drusen

Submitted: November 13, 2014.

Final revision submitted: December 25, 2014.

Accepted: January 22, 2015.

From the Department of Ophthalmology and Visual Science (Nagai, Hirano, Yasukawa, Morita, Nozaki, Ogura), Nagoya City University Graduate School of Medical Sciences, Nagoya, Japan, and the Department of Ophthalmology (Wolf-Schnurrbusch, Wolf), University of Bern, Bern, Switzerland.

Hoya Corp., Tokyo, Japan, provided data analysis of fundus autofluorescence imaging of all the patients at the Bern Photographic Reading Center.

Presented at the 12th Congress of the European Society of Retina Specialists, Milan, Italy, September 2012.

Corresponding author: Yoshio Hirano, MD, PhD, Tsutomu Yasukawa, MD, PhD, Department of Ophthalmology and Visual Science, Nagoya City University Graduate School of Medical Sciences, 1-Kawasumi, Mizuho-cho, Mizuho-ku, Nagoya-shi, Aichi 467-8601, Japan. E-mail: yoshio.hirano@gmail.com, yasukawa@med.nagoya-cu.ac.jp.

Table 1. Baseline patient characteristics.

Patient Characteristic	Study Group		P Value
	Yellow-Tinted IOL (n = 52)	Colorless IOL (n = 79)	
Age (y)			
Mean ± SD	73.9 ± 8.9	75.5 ± 6.9	.26
Range	48, 86	50, 90	
Sex (n)			.61
Men	19	27	
Women	33	52	
Smoking (n)			.51
Never	30	36	
Past	4	29	
Current	6	9	
Unknown	12	5	
Diabetes (n)			.12
Yes	40	59	
No	7	11	
Unknown	5	9	
Hypertension (n)			.44
Yes	23	39	
No	23	31	
Unknown	6	9	
Supplements (n)			.55
None	36	64	
Lutein	1	4	
Multiple in AREDS formulation*	1	0	
Other	1	0	
Unknown	13	11	

AREDS = age-related eye disease study; IOL = intraocular lens
 *Vitamin C, vitamin E, beta-carotene, lutein/zeaxanthin, zinc

progressed in 3 eyes (3.8%) in the colorless IOL group; however, the difference did not reach statistical significance.

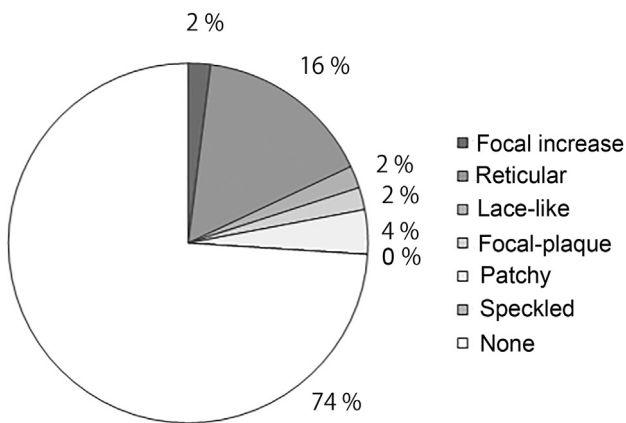


Figure 2. Incidence of abnormal fundus autofluorescence patterns at baseline.

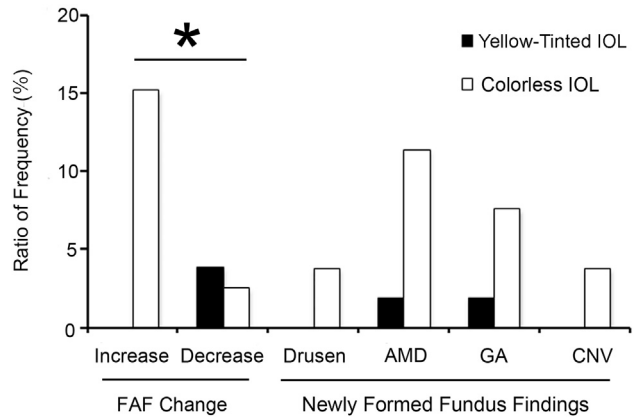


Figure 1. Frequency of changes in fundus autofluorescence and new fundus findings 2 years after cataract surgery. An asterisk indicates statistically significance (AMD = age-related macular degeneration; CNV = choroidal neovascularization; FAF = fundus autofluorescence; GA = geographic atrophy; IOL = intraocular lens).

Figure 2 shows the incidence of the abnormal fundus autofluorescence patterns at baseline. There were abnormal fundus autofluorescence patterns in 34 eyes (26.0%). The reticular pattern predominated in 21 eyes (16.0%). The patchy pattern was seen in 5 eyes (3.8%), the focal-increase pattern in 3 eyes (2.3%), the lace-like pattern in 3 eyes (2.3%), and the focal-plaque pattern in 2 eyes (1.5%).

Progression of AMD affected 3 (14.3%) of 21 eyes with the reticular pattern, 4 (80.0%) of 5 eyes with the patchy pattern, 1 (33.3%) of 3 eyes with the focal-increase pattern, 1 (33.3%) of 3 eyes with the lace-like pattern (33.3%), and 1 (1.0%) of 97 eyes with the normal pattern ($P < .001$) (Figure 3). Nine (26.5%) of 34 eyes with any abnormal fundus autofluorescence patterns had advanced AMD after cataract surgery. These eyes had a statistically

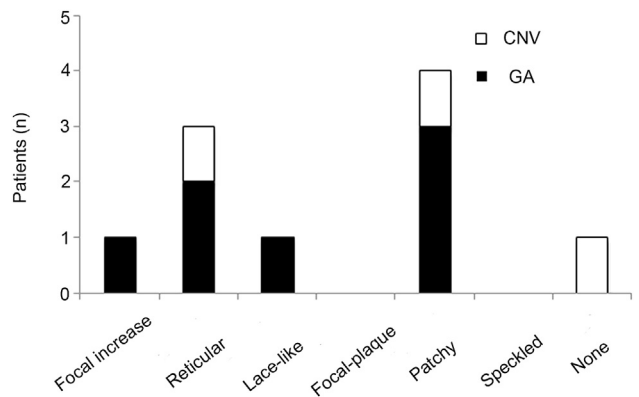


Figure 3. Number of patients with progression of AMD 2 years after cataract surgery according to each baseline fundus autofluorescence pattern (CNV = choroidal neovascularization; GA = geographic atrophy).

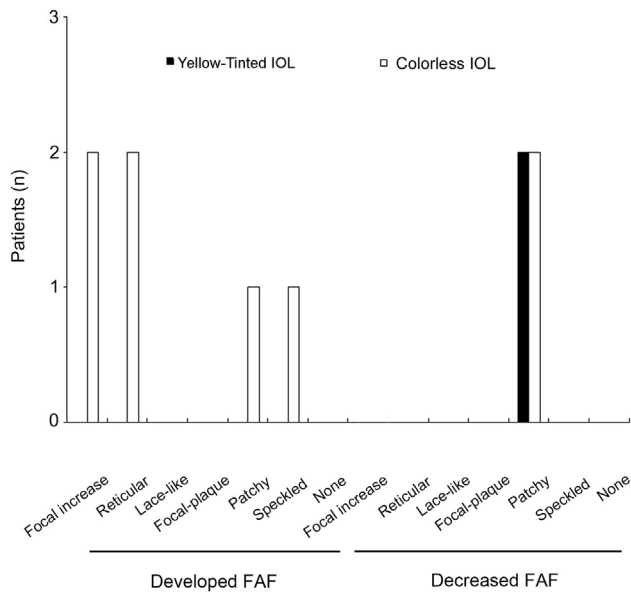


Figure 4. Number of patients with abnormal fundus autofluorescence changes after surgery (FAF = fundus autofluorescence; IOL = intraocular lens).

significantly higher incidence of AMD after cataract surgery than 1.0% of eyes with normal fundus autofluorescence ($P < .001$). Among the abnormal fundus autofluorescence patterns, the patchy pattern was associated with the highest risk for AMD progression postoperatively.

Figure 4 shows the abnormal fundus autofluorescence patterns, which changed from baseline to 2 years. New abnormal fundus autofluorescence developed in 6 eyes and decreased in 4 eyes. New abnormal fundus autofluorescence developed only in eyes in the colorless IOL group. However, decreases in preexisting abnormal fundus autofluorescence were observed only in eyes with the patchy pattern, independent of the type of IOL implanted.

DISCUSSION

It remains controversial whether cataract surgery increases the risk for AMD development. Some long-term population-based studies¹⁻³ report an approximately 3 times higher incidence of AMD in pseudophakic eyes than in phakic eyes. In contrast, the Age-Related Eye Disease Study⁷ found that cataract surgery did not have a significant impact on the incidence of AMD. The enrolled patients were highly educated and had an increased intake of antioxidants and minerals. Thus, the impact of cataract surgery on the incidence of AMD remains to be elucidated.

The blue-light hazard after cataract surgery is another possible factor in the incidence of AMD and

might be reduced by implantation of a yellow-tinted IOL. In vitro studies^{8,9} found that a yellow-tinted IOL protected RPE cells from light exposure and inhibited production of vascular endothelial growth factor stimulated by exposure to blue light. In a study by Obana et al.,¹⁰ the macular pigment optical density measured by resonance Raman spectroscopy decreased in eyes with a colorless IOL; such a decrease might be associated with the risk for AMD development. Based on those studies, Braunstein and Sparrow¹¹ proposed that a yellow-tinted IOL should be used to reduce the risk for or progression of AMD. However, Kara-Junior et al.¹² found no significant differences in central macular thickness measured by optical coherence tomography, in contrast sensitivity, or in color vision between eyes with a yellow-tinted IOL and eyes with a colorless IOL after 5 years of follow-up; they concluded that the potential advantages of yellow-tinted IOLs in protecting the macula remain unclear. The present study assessed only the clinical findings related to advanced AMD, which might make it difficult to determine whether using a yellow-tinted IOL has a significant impact.

Abnormal fundus autofluorescence has been recognized as predictive of development of geographic atrophy or wet AMD. In a study by Holz et al.,¹³ increased fundus autofluorescence preceded new formation or enlargement of geographic atrophy. Alterations in fundus autofluorescence are not necessarily associated with funduscopic visible drusen or pigment epithelial alterations.⁴ Thus, abnormal fundus autofluorescence might be an early and predictive sign of AMD. For this reason, we performed this fundus autofluorescence imaging and fundus photography study. In our study, increased fundus autofluorescence was seen in the colorless IOL group only, suggesting that the yellow-tinted IOL protects against the postoperative blue-light hazard (Figure 1).

Among the abnormal baseline fundus autofluorescence patterns, the patchy pattern was more likely to be associated with development of geographic atrophy or wet AMD. The patchy pattern often resolved, independent of the type of IOL implanted. The patchy pattern is characterized by the presence of at least 1 large area ($> 200 \mu\text{m}$ diameter) of markedly increased fundus autofluorescence.⁴ Batioğlu et al.¹⁴ found that the patchy pattern was most frequently associated with the progression of choroidal neovascularization (CNV), which might support our findings. The patchy pattern often corresponds to large drusen or drusenoid pigment epithelial detachment, both of which are risk factors for AMD. In clinical trials of prophylactic grid laser photocoagulation for prevention of AMD,¹⁵ the enrollment of which was suspended because of an increased incidence of CNV within 12

months of study enrollment, the percentage of eyes with a 50% reduction in the area of drusen in the laser treatment group was statistically significantly higher than in the observation group. The results in that study suggest that grid laser-induced inflammation reduces drusen but potentially causes CNV. We speculate that, in the same manner, intraocular surgery-related postoperative inflammation might reduce the patchy pattern in some cases but can cause CNV in other cases, independent of IOL types.

The limitations of this study are the small number of enrolled patients and the nonrandomized design. A comparative randomized study with more patients and a longer follow-up is needed to confirm the protective effects of yellow-tinted IOLs on the incidence of AMD.

In conclusion, after 2 years of observation, abnormal fundus autofluorescence increased in some eyes with implantation of UV light-filtering IOLs. Blue light-filtering IOLs might prevent AMD. Wet AMD or geographic atrophy often develops in eyes in which the patchy pattern is observed preoperatively.

WHAT WAS KNOWN

- Cataract surgery might increase the risk for development of AMD.

WHAT THIS PAPER ADDS

- Fundus autofluorescence imaging after cataract surgery might indicate the risk for AMD progression in eyes with the colorless IOLs.

REFERENCES

1. Klein R, Klein BEK, Wong TY, Tomany SC, Cruickshanks KJ. The association of cataract and cataract surgery with the long-term incidence of age-related maculopathy; the Beaver Dam Eye Study. *Arch Ophthalmol* 2002; 120:1551–1558. Available at: <http://archophth.jamanetwork.com/data/Journals/OPHTH/6842/EEB20011.pdf>. Accessed June 28, 2015
2. Freeman EE, Munoz B, West SK, Tielsch JM, Schein OD. Is there an association between cataract surgery and age-related macular degeneration? Data from three population-based studies. *Am J Ophthalmol* 2003; 135:849–856
3. Cugati S, Mitchell P, Rochtchina E, Tan AG, Smith W, Wang JJ. Cataract surgery and the 10-year incidence of age-related maculopathy; the Blue Mountains Eye Study. *Ophthalmology* 2006; 113:2020–2025
4. Einböck W, Moessner A, Schnurrbusch UE, Holz FG, Wolf S. Changes in fundus autofluorescence in patients with age-related maculopathy. Correlation to visual function: a prospective study. *Graefes Arch Clin Exp Ophthalmol* 2005; 243:300–305
5. Lois N, Owens SL, Coco R, Hopkins J, Fitzke FW, Bird AC. Fundus autofluorescence in patients with age-related macular degeneration and high risk of visual loss. *Am J Ophthalmol* 2002; 133:341–349
6. Early Treatment Diabetic Retinopathy Study Research Group. Early Treatment Diabetic Retinopathy Study Design and Baseline Patient Characteristics. ETDRS report number 7. *Ophthalmology* 1991; 98:741–756
7. Chew EY, Sperduto RD, Milton RC, Clemons TE, Gensler GR, Bressler SB, Klein R, Klein BEK, Ferris FL III. Risk of advanced age-related macular degeneration after cataract surgery in the Age-Related Eye Disease Study: AREDS report 25. *Ophthalmology* 2009; 116:297–303. Available at: <http://www.ncbi.nlm.nih.gov/pmc/articles/PMC3021282/pdf/nihms92134.pdf>. Accessed June 28, 2015
8. Sparrow JR, Miller AS, Zhou J. Blue light-absorbing intraocular lens and retinal pigment epithelium protection in vitro. *J Cataract Refract Surg* 2004; 30:873–878
9. Yanagi Y, Inoue Y, Iriyama A, Jang W-D. Effects of yellow intraocular lenses on light-induced upregulation of vascular endothelial growth factor. *J Cataract Refract Surg* 2006; 32:1540–1544
10. Obana A, Tanito M, Gohto Y, Gellermann W, Okazaki S, Ohira A. Macular pigment changes in pseudophakic eyes quantified with resonance Raman spectroscopy. *Ophthalmology* 2011; 118:1852–1858
11. Braunstein RE, Sparrow JR. A blue-blocking intraocular lens should be used in cataract surgery. *Arch Ophthalmol* 2005; 123:547–549
12. Kara-Junior N, Espindola RF, Gomes BAF, Ventura B, Smadja D, Santhiago MR. Effects of blue light-filtering intraocular lenses on the macula, contrast sensitivity, and color vision after a long-term follow-up. *J Cataract Refract Surg* 2011; 37:2115–2119
13. Holz FG, Bellmann C, Margaritidis M, Schütt F, Otto TP, Völcker HE. Patterns of increased in vivo fundus autofluorescence in the junctional zone of geographic atrophy of the retinal pigment epithelium associated with age-related macular degeneration. *Graefes Arch Clin Exp Ophthalmol* 1999; 237:145–152
14. Batioğlu F, Demirel S, Özmert E, Oguz YG, Özyol P. Autofluorescence patterns as a predictive factor for neovascularization. *Optom Vis Sci* 2014; 91:950–955
15. The Choroidal Neovascularization Prevention Trial Research Group. Laser treatment in fellow eyes with large drusen: updated findings from a pilot randomized clinical trial. *Ophthalmology* 2003; 110:971–978